



DENTAL FACTSHEET

Horse's teeth could hardly be more different than our own (see third picture above). They have 6 **incisor** teeth in the upper and lower jaws and then a large gap before the six **cheek** teeth. We use the term 'cheek teeth' to describe the premolar and molar teeth collectively. Male horses also have **canine** teeth which emerge at about 5 years of age in the gap between the incisors and molar teeth in both upper and lower jaws. They are only occasionally seen in mares.

Incisor and Canine Teeth

Problems with the incisor and canine teeth are thankfully rare and are mainly the result of trauma, such as kicks from other field-mates or hooking their teeth on a hay net.

Some geldings develop **tartar and calculus** on their canine teeth and require this to be cracked off each year. Unless the diet is excessively high in sugars or acids they rarely develop cavities like their sweet toothed owners! Incisor teeth start to wear out in the mid to late 20's but this is variable.

Cheek Teeth

These are termed **hypsoodontal** which means that, unlike our's, they do not have a distinct **crown** above the gum and **root** below. The tooth is of a similar make up throughout its entire length, and continues to erupt at a rate of 2-3mm per year throughout the horse's life.

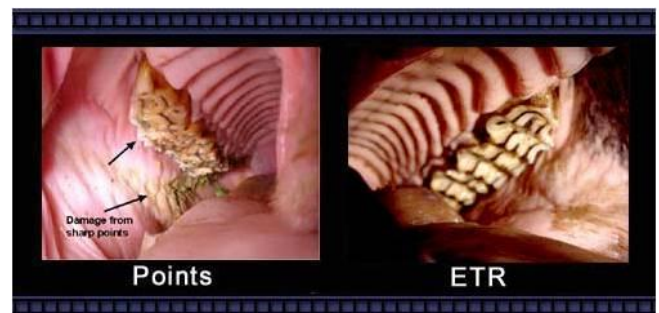
The constant grinding action of a horse chewing wears away the emerging tooth. In the wild the rough forage and sand picked up with grazing means this process of **emergence versus wear** remains in fine balance.

However, with nicely manicured pasture and soft palatable concentrate feeds the teeth don't wear away as fast as they would in the wild and so develop overgrowths of enamel at the grinding edges of the upper and lower cheek teeth.

Routine Dental Care

Your horse should have its teeth checked **annually** by an equine vet or an accredited Equine Dental Technician (EDT). It is important that you take the time to ensure the person you are trusting with your horse's teeth is a properly qualified. **ANYBODY** can call themselves an 'equine dentist' with absolutely no training or qualification.

The vast majority of routine dental care is to address this issue of enamel overgrowths, which develop into sharp points (below left) or enamel transverse ridges (ETR, below right).

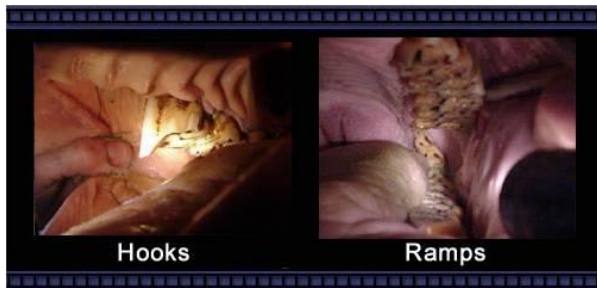

If left untreated the commonest signs of enamel overgrowths are:

- **Quidding** - dropping food.
- **Balling** – food pouches in the cheeks like a hamster
- **Inappetence** - reluctance to eat
- **Tossing of the head** or biting discomfort.

Smaller enamel overgrowths can be easily removed with a hand rasp or 'float'. A **gag must be placed** in your horse's mouth to safely and properly inspect and rasp the teeth. About 1 in 20 horses find this frightening and require light sedation. The way to avoid this is to have your horse checked each year from two years old so that they are used to having the gag put in their mouth. Most horses do not need any actual rasping until they are 4 or 5 year olds when they have all their adult cheek teeth in place.

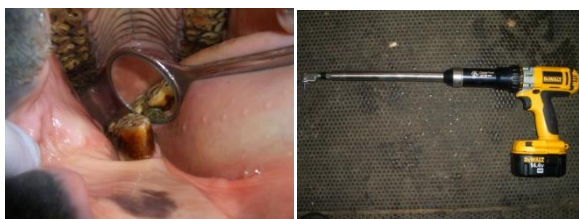Some horses will need these enamel overgrowths removed twice yearly. More severe overgrowths – hooks and ramps (see below) - do occur and are often caused by malformation of the teeth such that they do not have an opposing tooth to wear against.



Hooks and ramps require motorised burrs to remove these large areas of diamond-hard enamel. They commonly recur at the same rate that the tooth is erupting, *i.e.* 2-3 mm/yr, and so require treatment every year or so.

Diastema

Diastema are caused by malformation of the teeth so that food jams between two adjacent cheek teeth. Daily grinding packs more and more food into the tiny space, eventually forcing food under the gum line. Diastema can be difficult to identify, often requiring the use of a dental mirror. The picture on the left below shows food jammed at the '6 o'clock' position in the mirror.



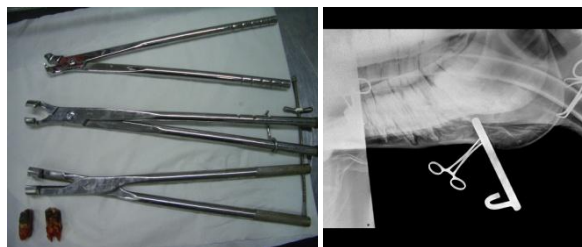Diastema are a common cause of oral pain and require specialist treatment to either widen the space between the two teeth, allowing the food to move freely in and out of the gap, or to extract the cheek tooth if it has become diseased.

It is important to identify diastema early as widening the space can save the tooth. The gap is widened using a special motorised burr (above right). This procedure may require repeating as the teeth grow and the gap closes.

Cheek Teeth Fractures and Abscesses

Fractures and abscesses involving the cheek teeth invariably require extraction of the offending tooth. This is a major undertaking in horses due to the massive length of the 'root'.

Traditionally teeth were extracted by making a hole in the face (for an upper tooth) or the jaw (for a lower tooth) and hammering out the tooth. Now it is much more common to extract teeth from the mouth by using large dental extractors (below left) to loosen a diseased tooth and pull it free.



Oral extractions require substantial patience as it can take 6-8 hours to wiggle the tooth loose. Great care has to be taken not to fracture the tooth or leave fragments behind. The teeth at the bottom left of the picture above are from a 20 year-old horse and only a third of the length of those in 7 year-old.

Occasionally, and especially in young horses, it is not possible to extract a tooth orally. In these cases the horse is anaesthetised and a dental punch inserted through a hole made in the jaw bone or face to hammer out the tooth. The picture on the right above shows an Xray taken during surgery to check that the dental punch is correctly positioned prior to being hammered.

Wolf Teeth

About a third of horses have wolf teeth that erupt just in front of the cheek teeth between 1 and 8 years of age. They serve no purpose and are a remnant of the first pre-molar tooth that is no longer required. About 50% of horses need to have it removed as it interferes with the bit. This is easily done under light sedation.

There are many areas not covered in this fact sheet but we hope it has helped you understand your horse's mouth. Horses have quite amazing teeth and a simple check up at vaccination time should keep them that way.